

Two-Dimensional Echocardiography A Comprehensive Approach

J Poelaert, MD, PhD

**Cardiac Anaesthesia and Postoperative Cardiac
Surgical ICU**

Ghent University Hospital

Gent, Belgium

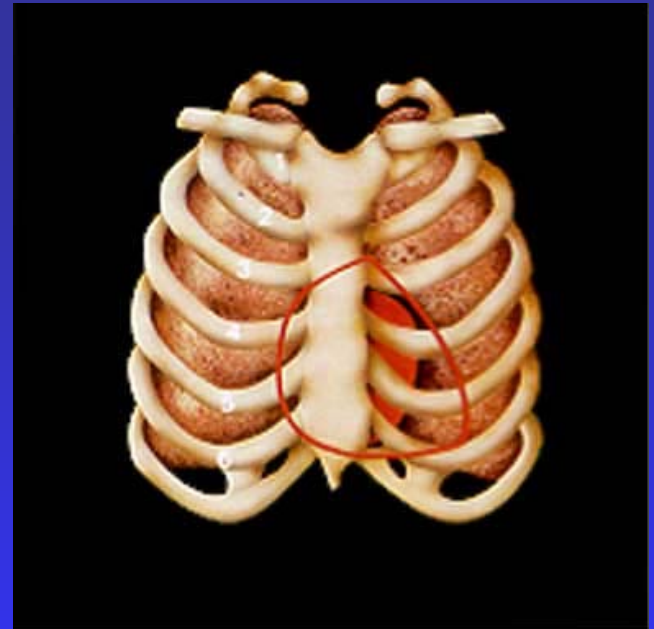
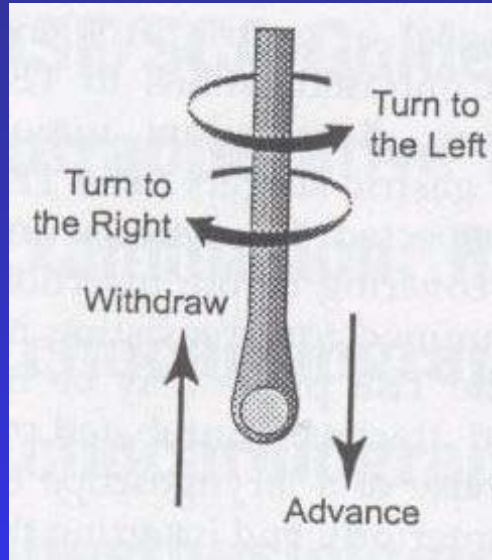
Two-Dimensional Echocardiography

A Comprehensive Approach Outline

- **Transverse plane + indications**
- **Longitudinal plane + indications**
- **Multiplane echocardiography + indications**

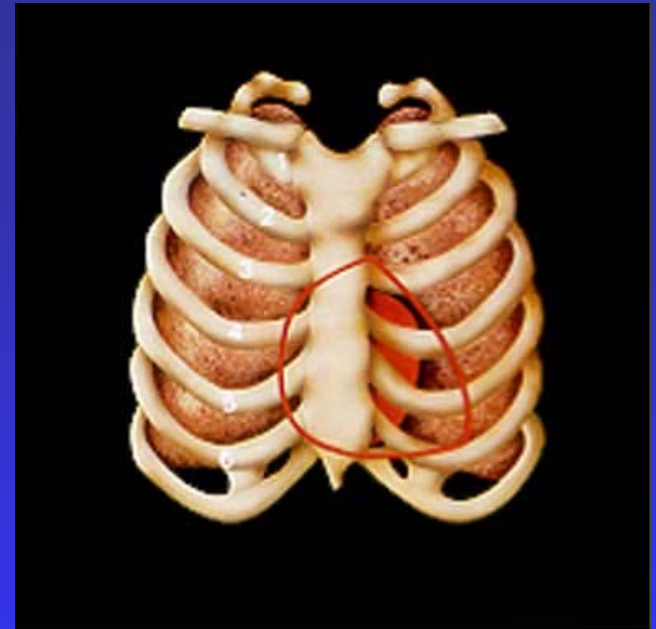
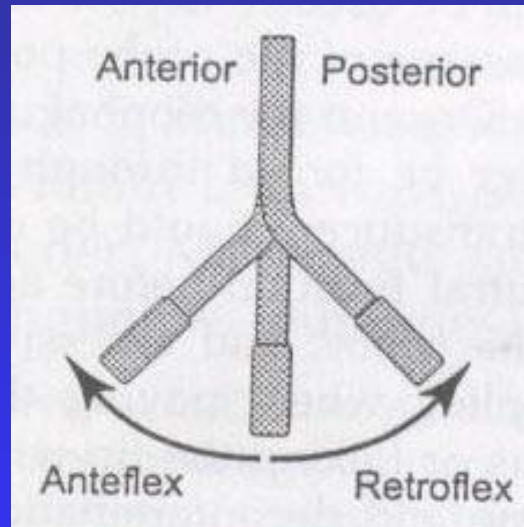
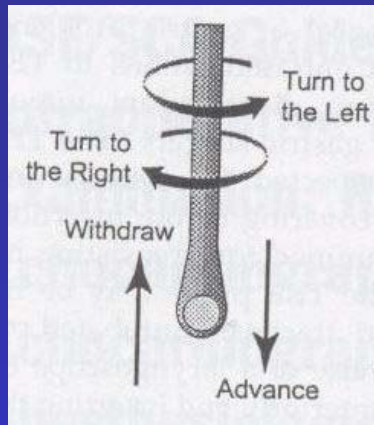
Two-Dimensional Echocardiography

A Comprehensive Approach



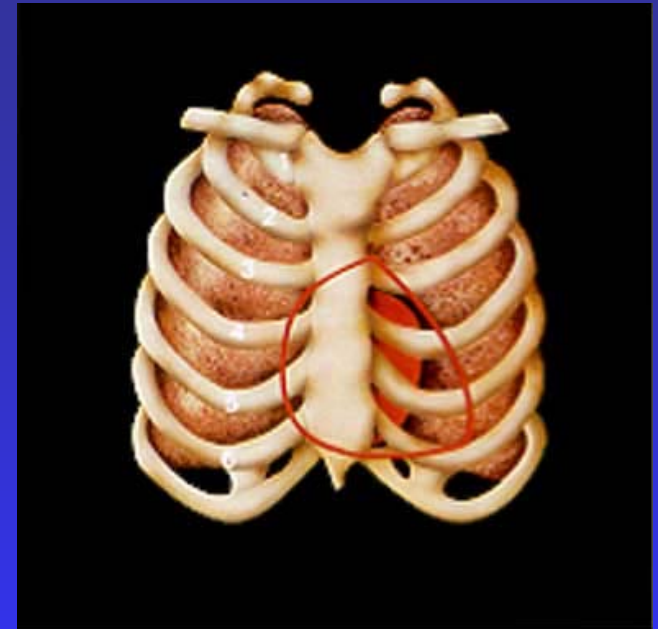
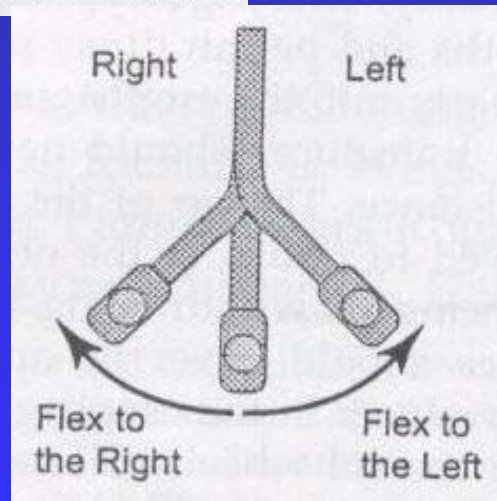
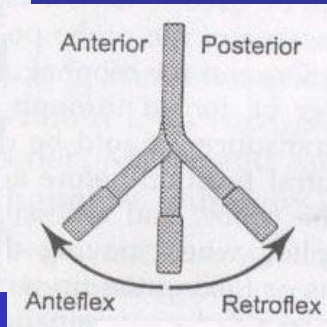
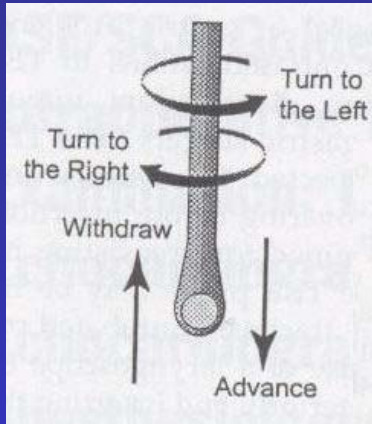
Two-Dimensional Echocardiography

A Comprehensive Approach



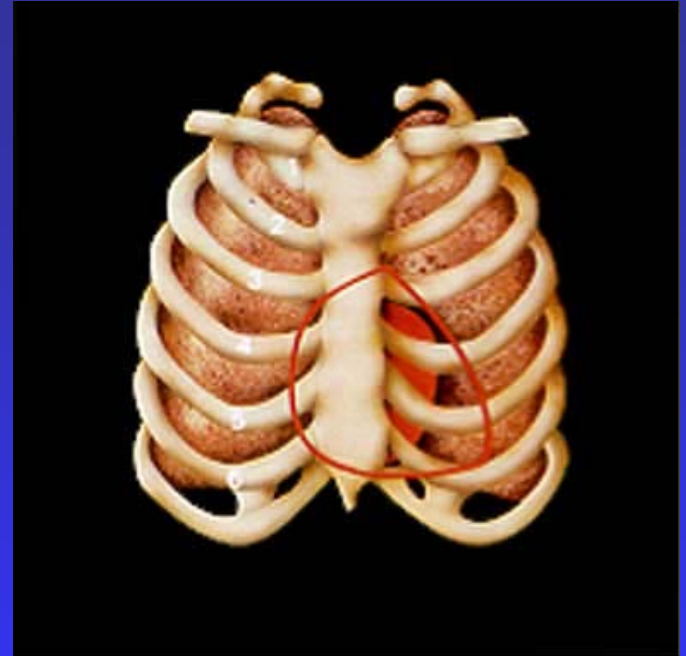
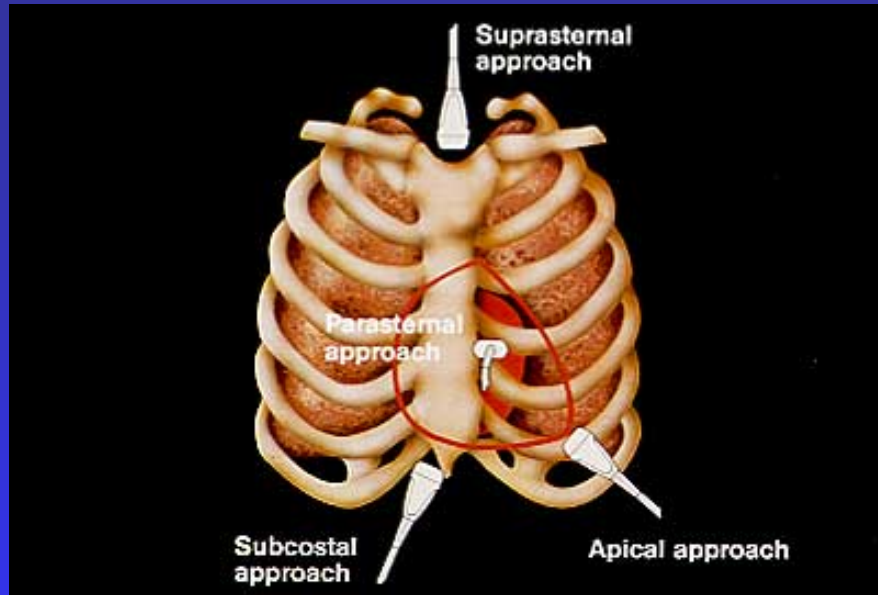
Two-Dimensional Echocardiography

A Comprehensive Approach



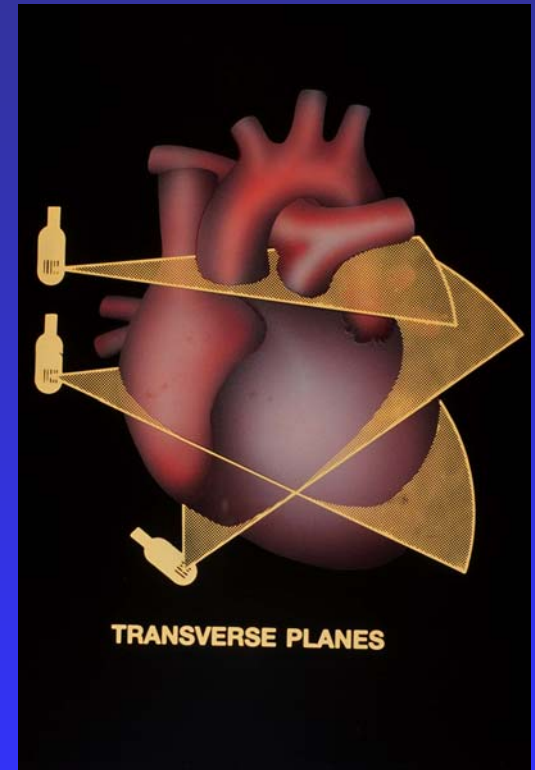
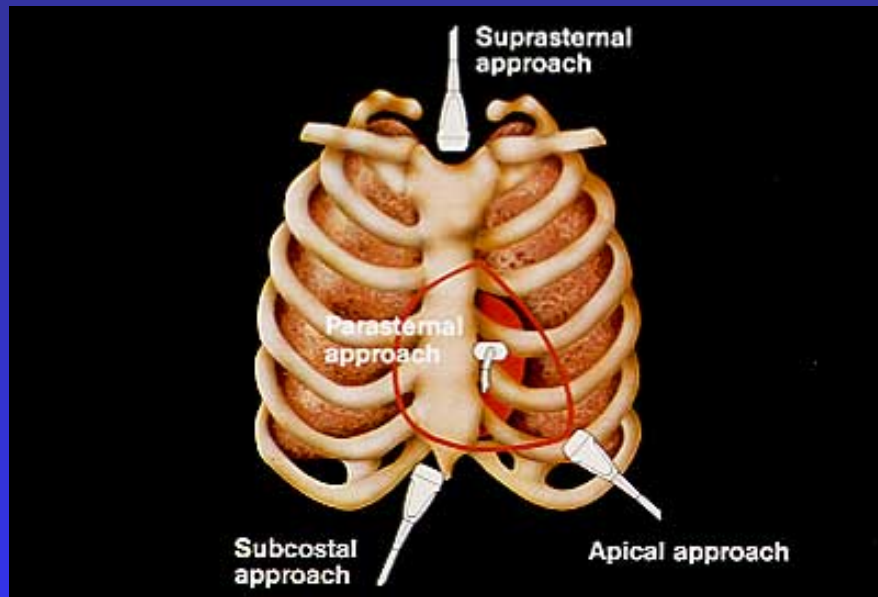
Two-Dimensional Echocardiography

A Comprehensive Approach



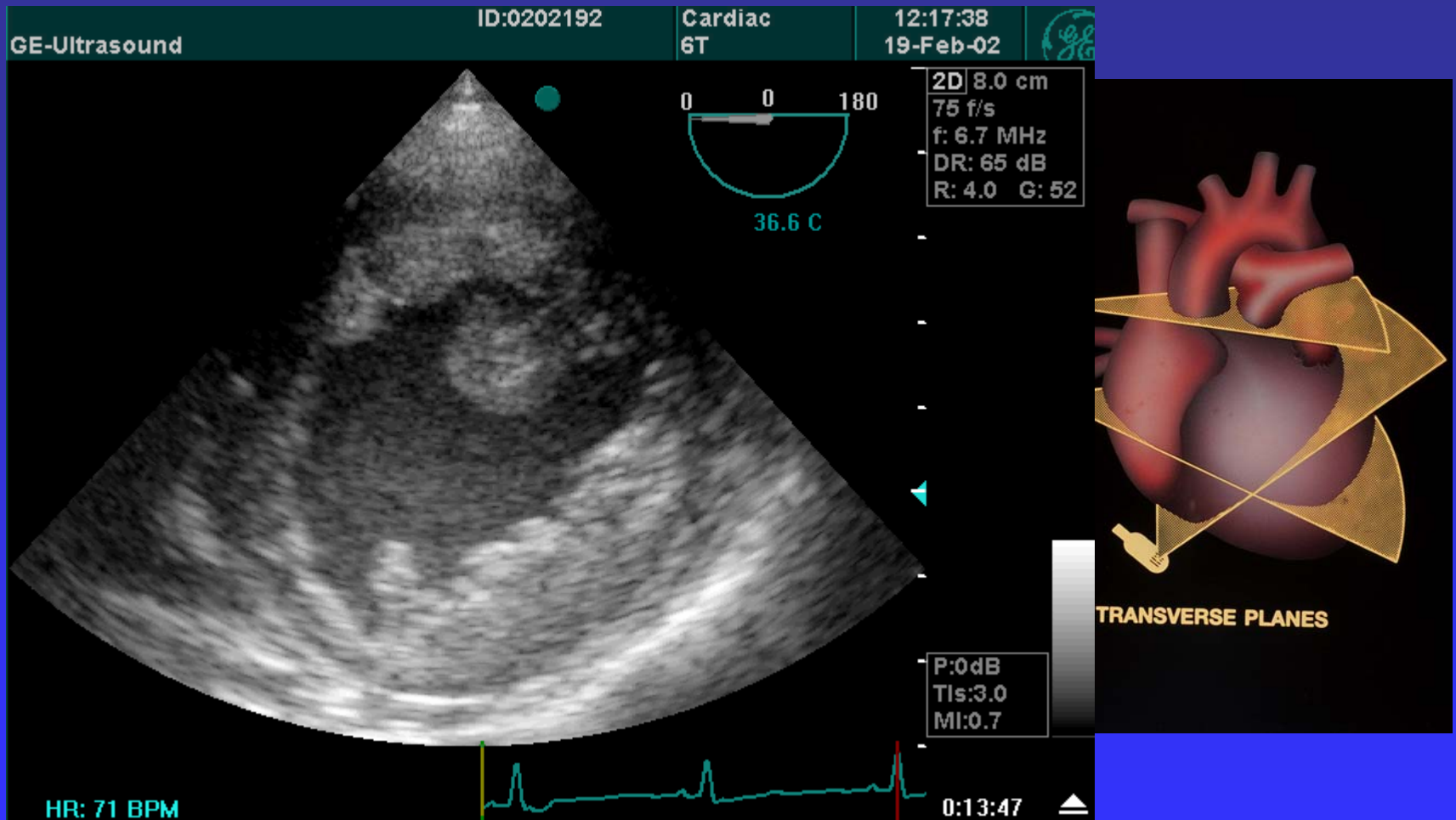
Two-Dimensional Echocardiography

A Comprehensive Approach



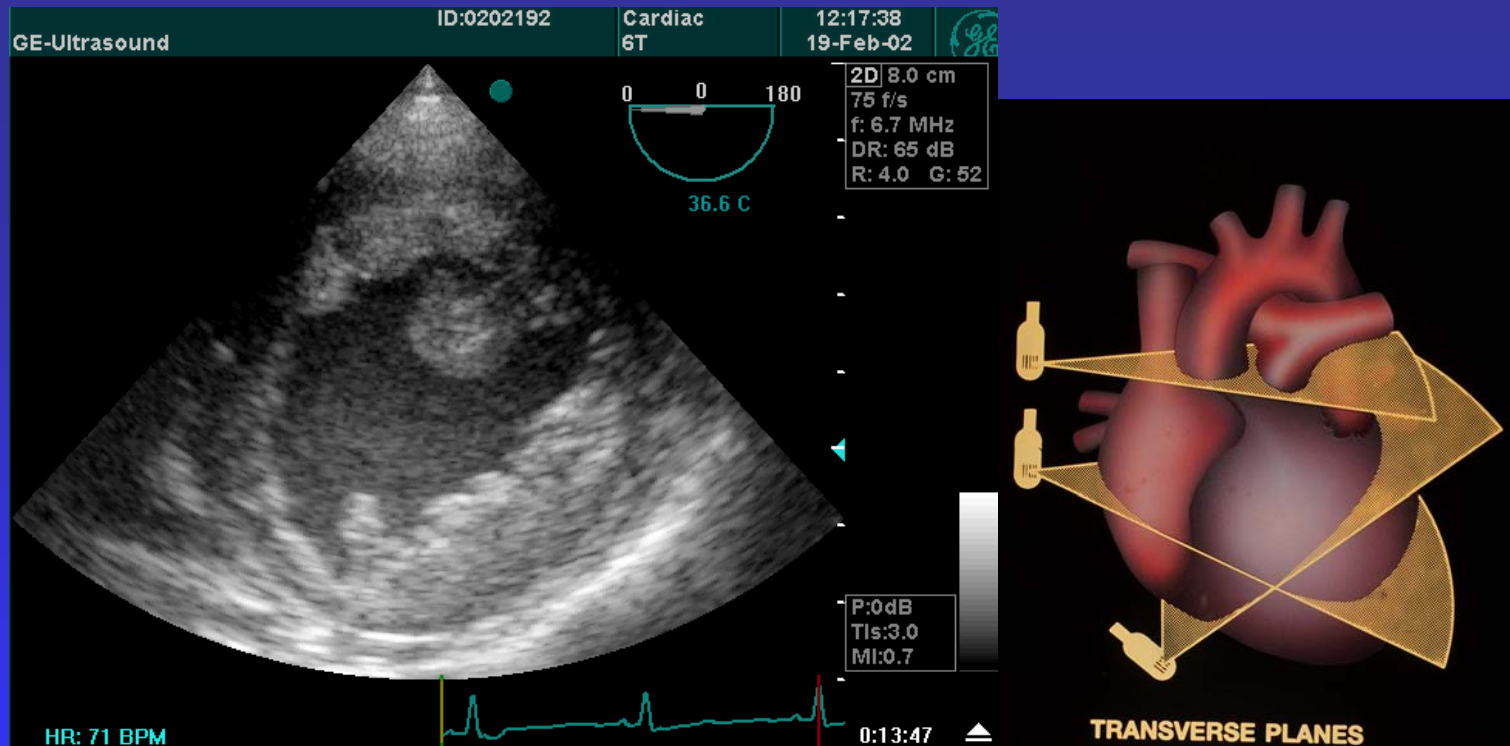
Two-Dimensional Echocardiography

A Comprehensive Approach



Two-Dimensional Echocardiography

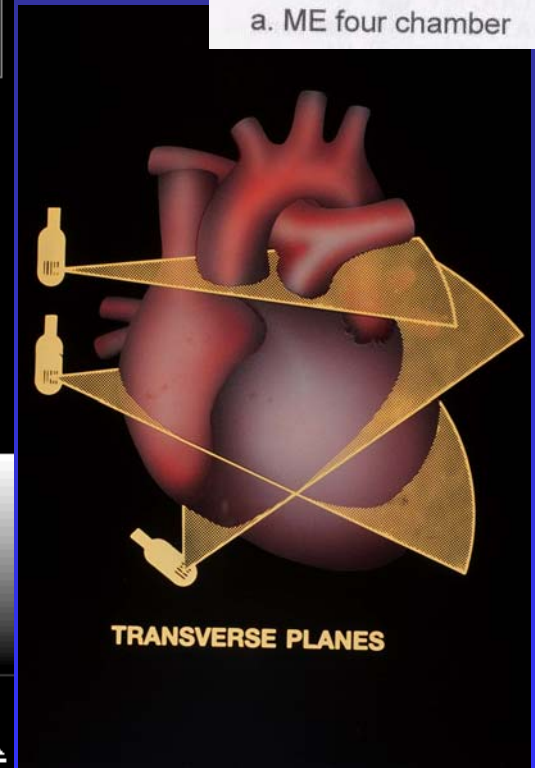
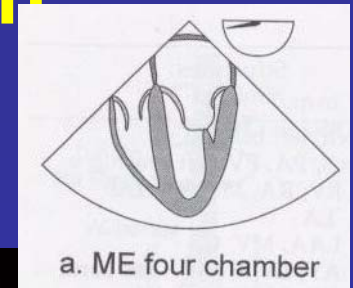
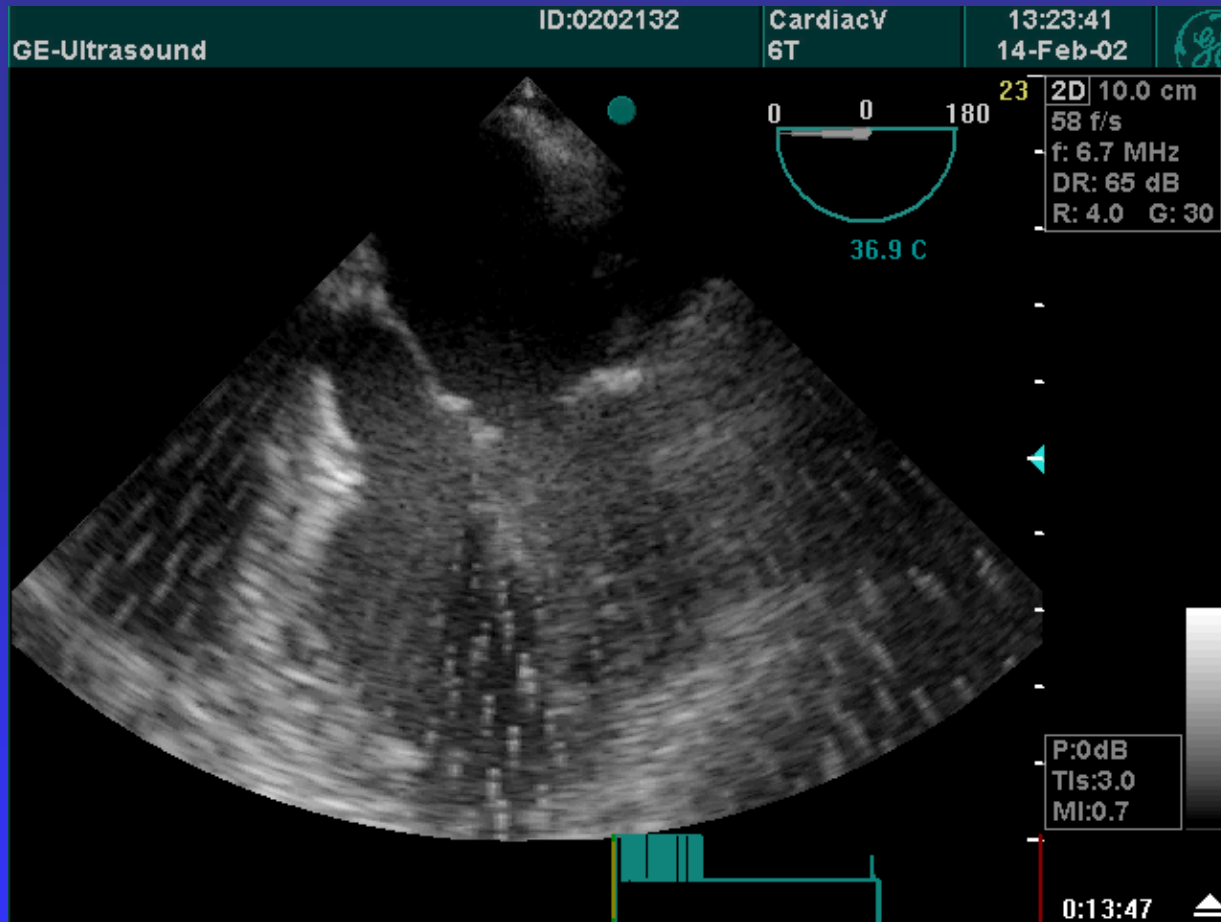
A Comprehensive Approach



1. Global ventricular function
2. Regional wall motion abnormalities
3. Preload

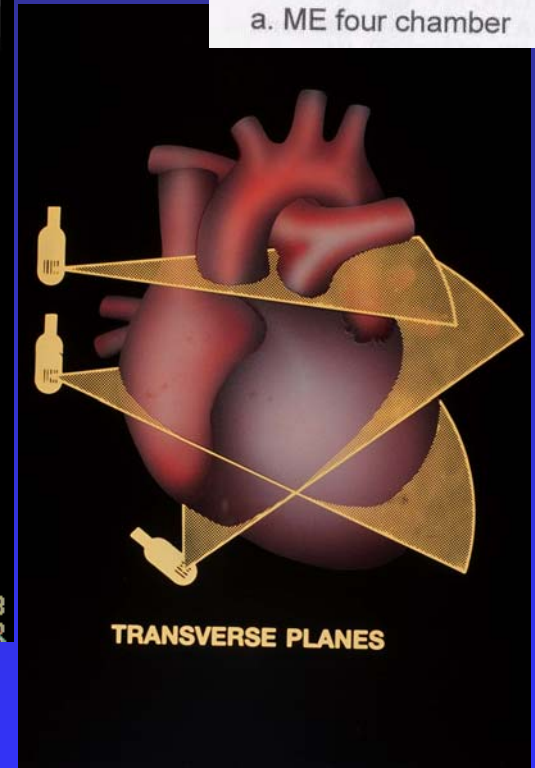
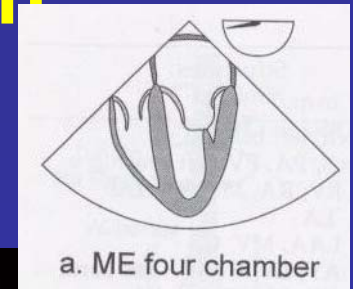
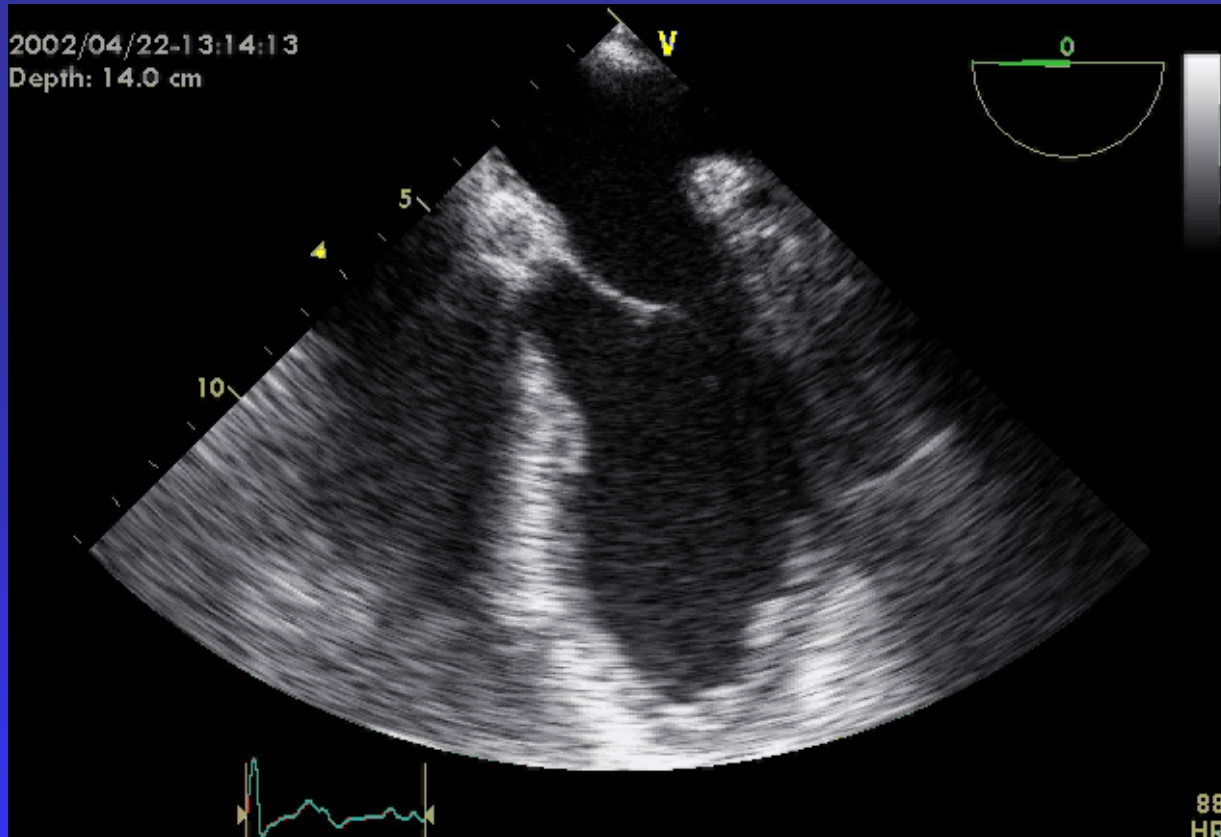
Two-Dimensional Echocardiography

A Comprehensive Approach



Two-Dimensional Echocardiography

A Comprehensive Approach



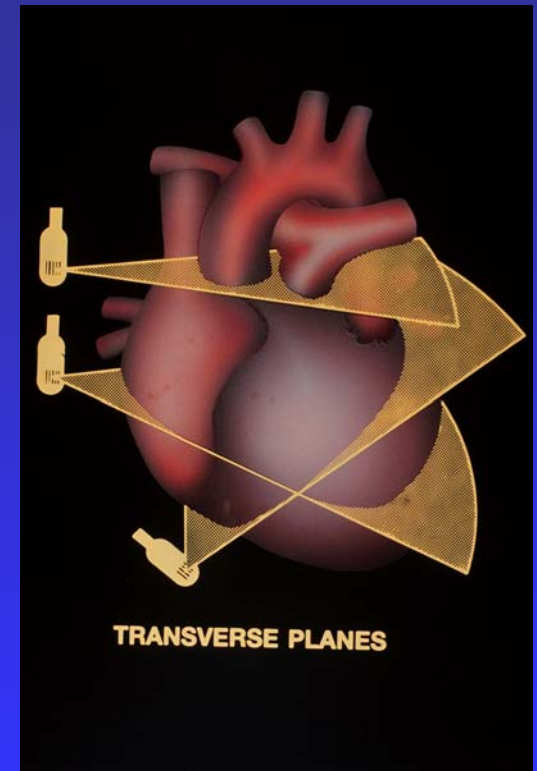
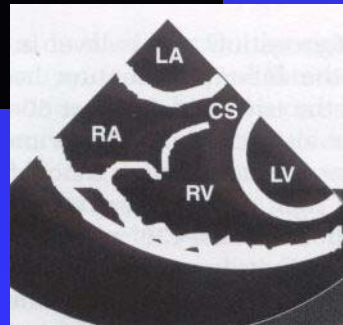
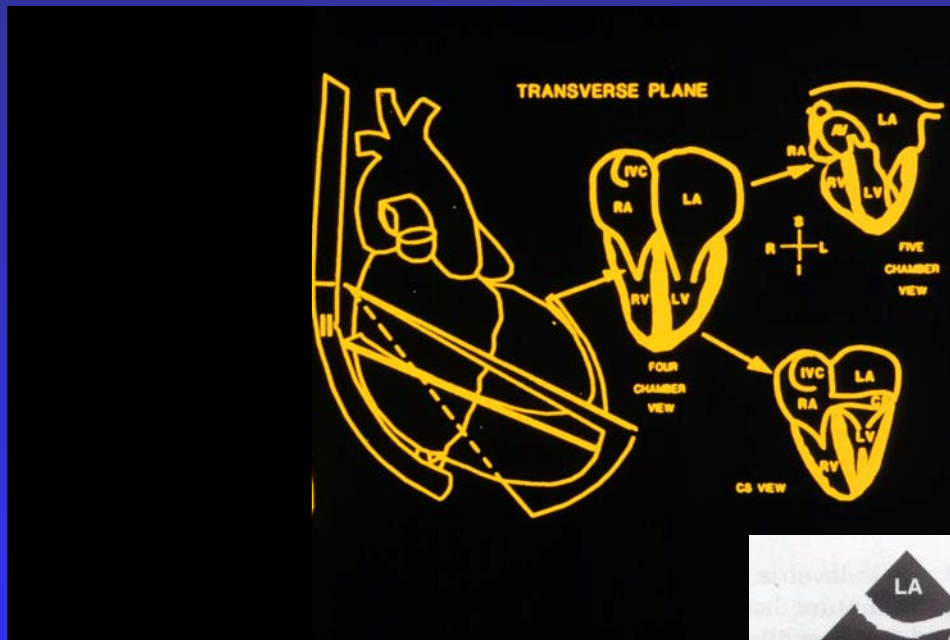
Two-Dimensional Echocardiography

A Comprehensive Approach

- **ME four chamber view indications:**
 - **Movement of IVS**
 - **Movement of free wall**
 - **Movement of mitral valve apparatus**
 - **Evaluation of mitral valve (T)**

Two-Dimensional Echocardiography

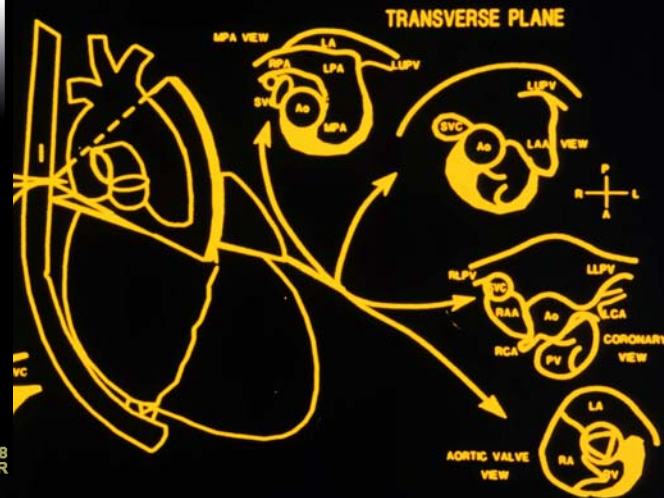
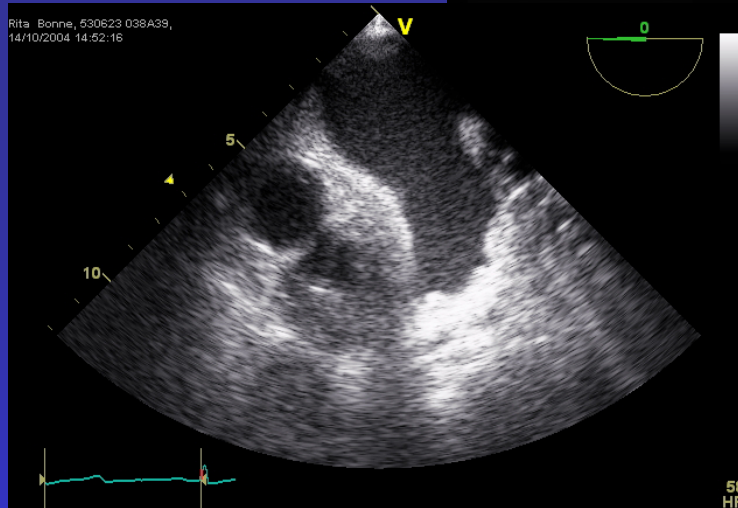
A Comprehensive Approach



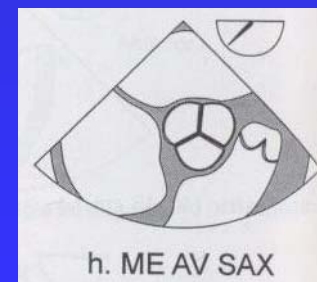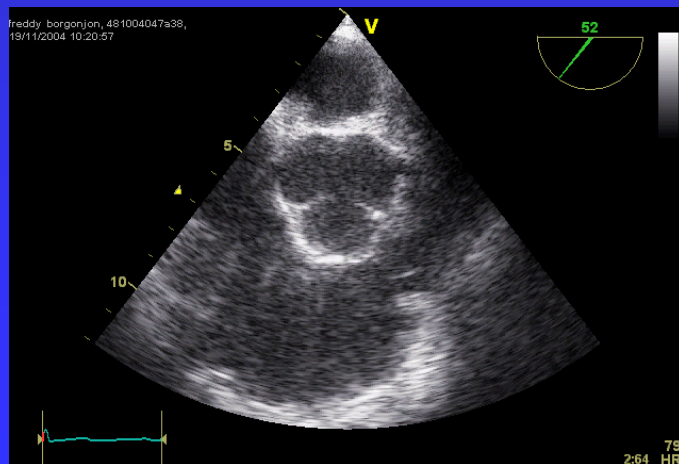
Two-Dimensional Echocardiography

A Comprehensive Approach

Rita_Bonne, 530623 038A39,
14/10/2004 14:52:16

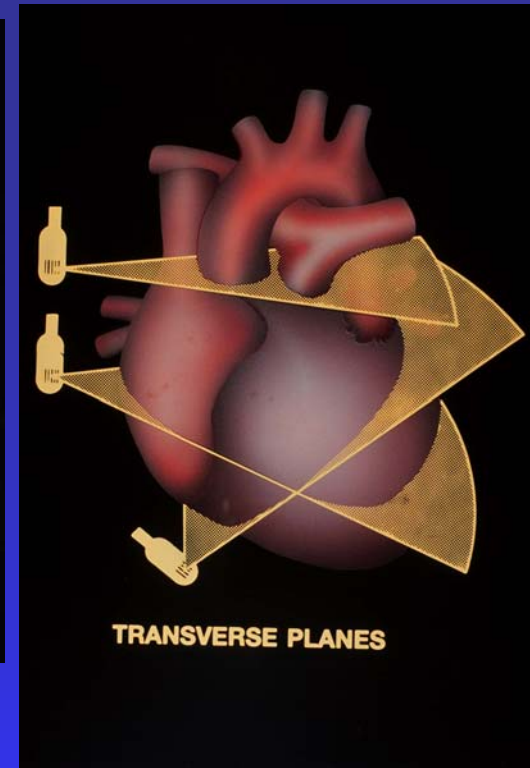
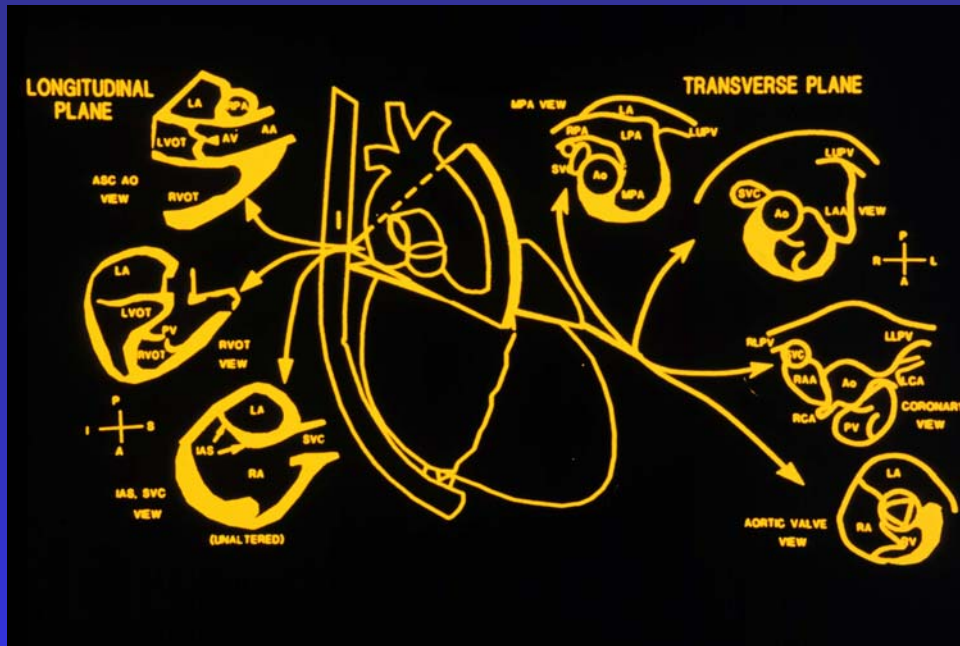


freddy_borgonjon, 481004047a38,
19/11/2004 10:20:57



Two-Dimensional Echocardiography

A Comprehensive Approach



Seward et al. Mayo Clin Proc 1988;63:649-80

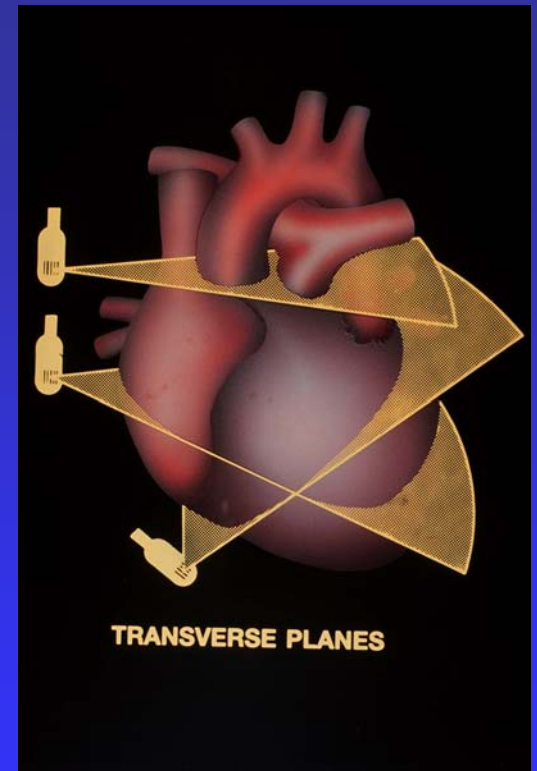
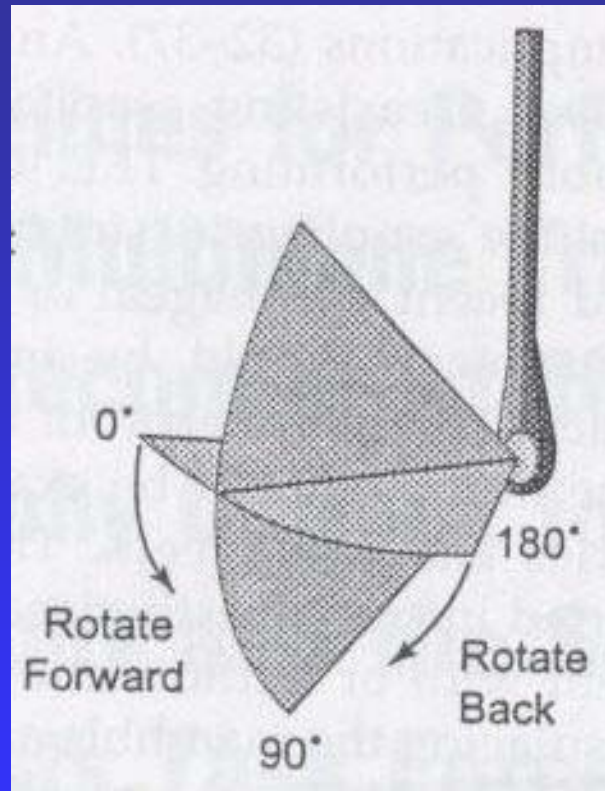
Seward et al. Mayo Clin Proc 1990;65:1193-1213

Visser et al. J Cardiothor Vasc Anesth 1988; 2:74-81

Poelaert et al. Anaesthesia 1998; 53:55-68

Two-Dimensional Echocardiography

A Comprehensive Approach



Two-Dimensional Echocardiography

A Comprehensive Approach

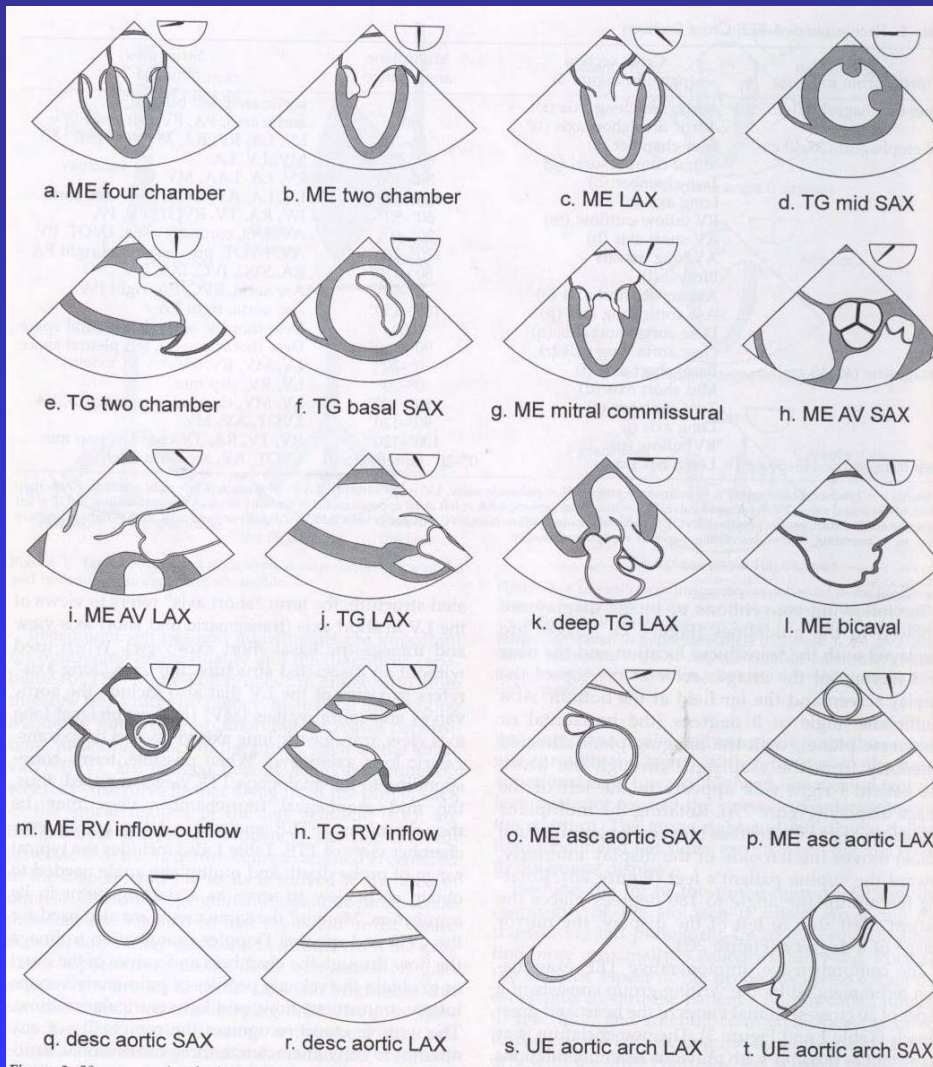
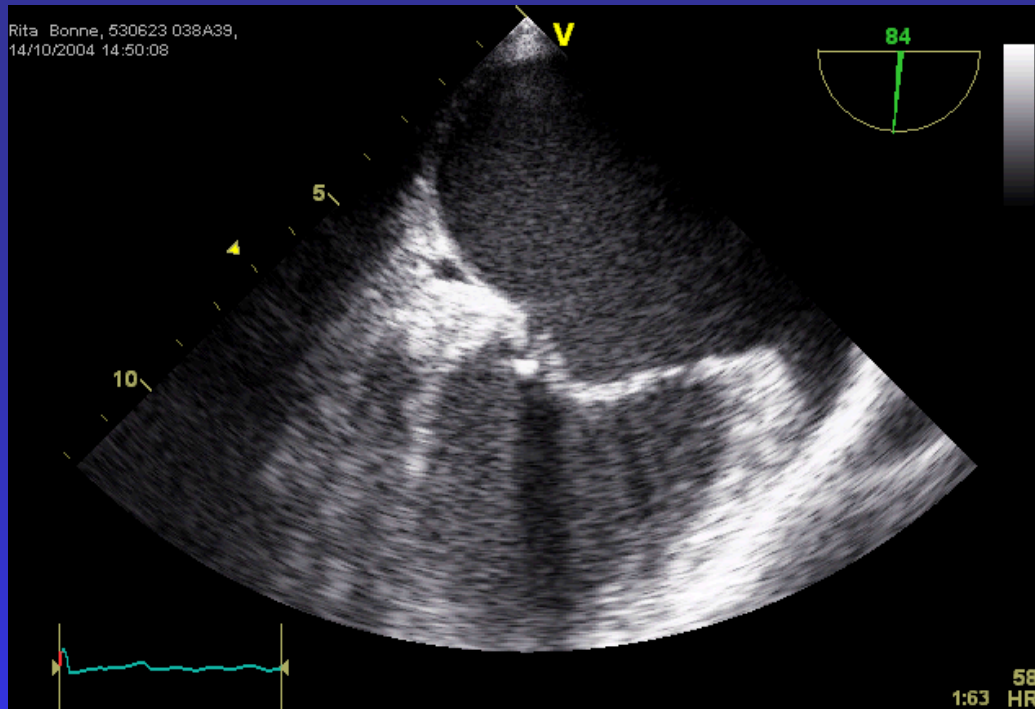


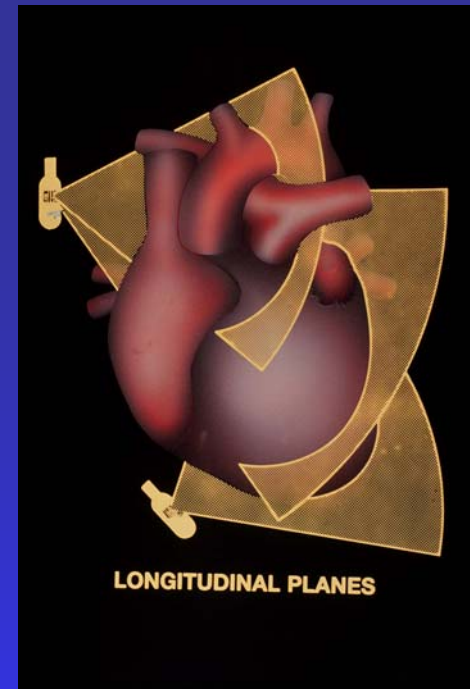
Figure 3-20. cross-sectional views commonly used in echocardiography.

Two-Dimensional Echocardiography

A Comprehensive Approach

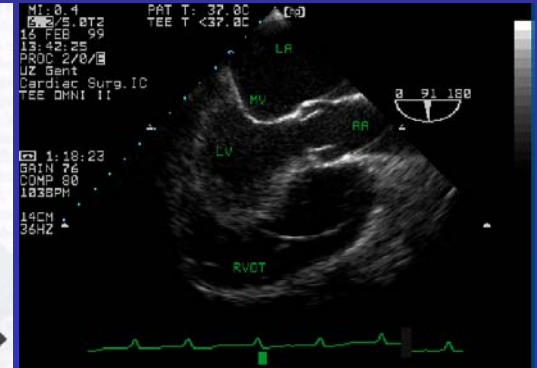
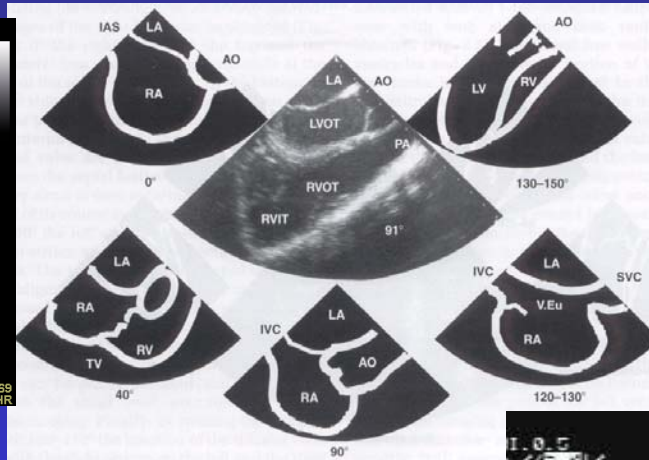
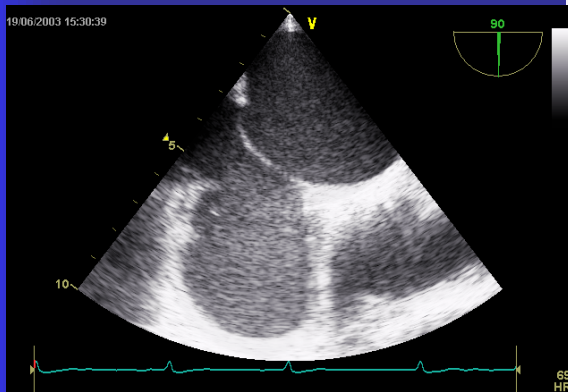


ME LAX

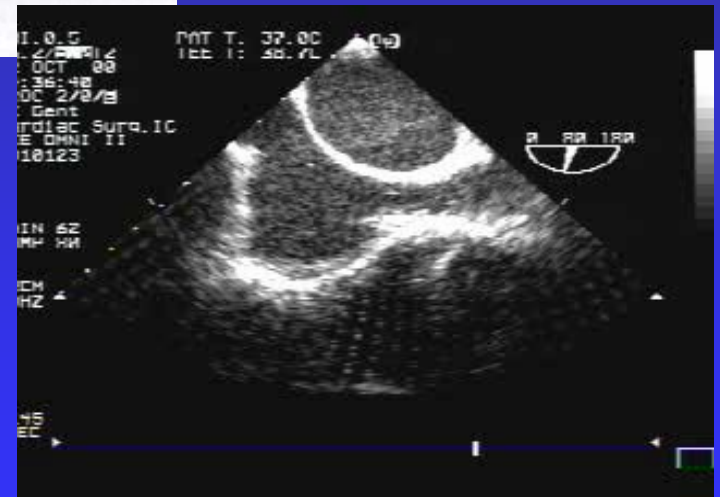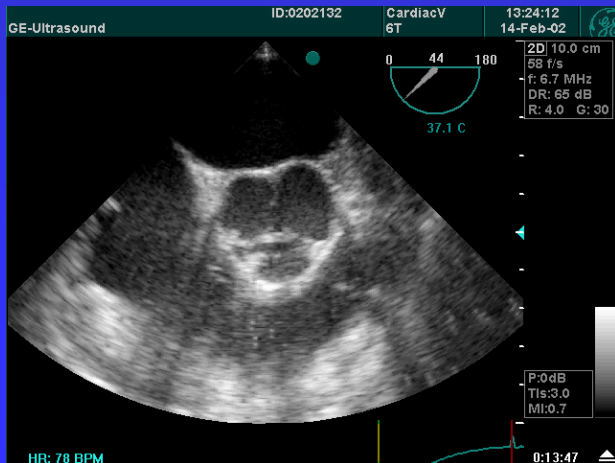


Two-Dimensional Echocardiography

A Comprehensive Approach: ME LAX



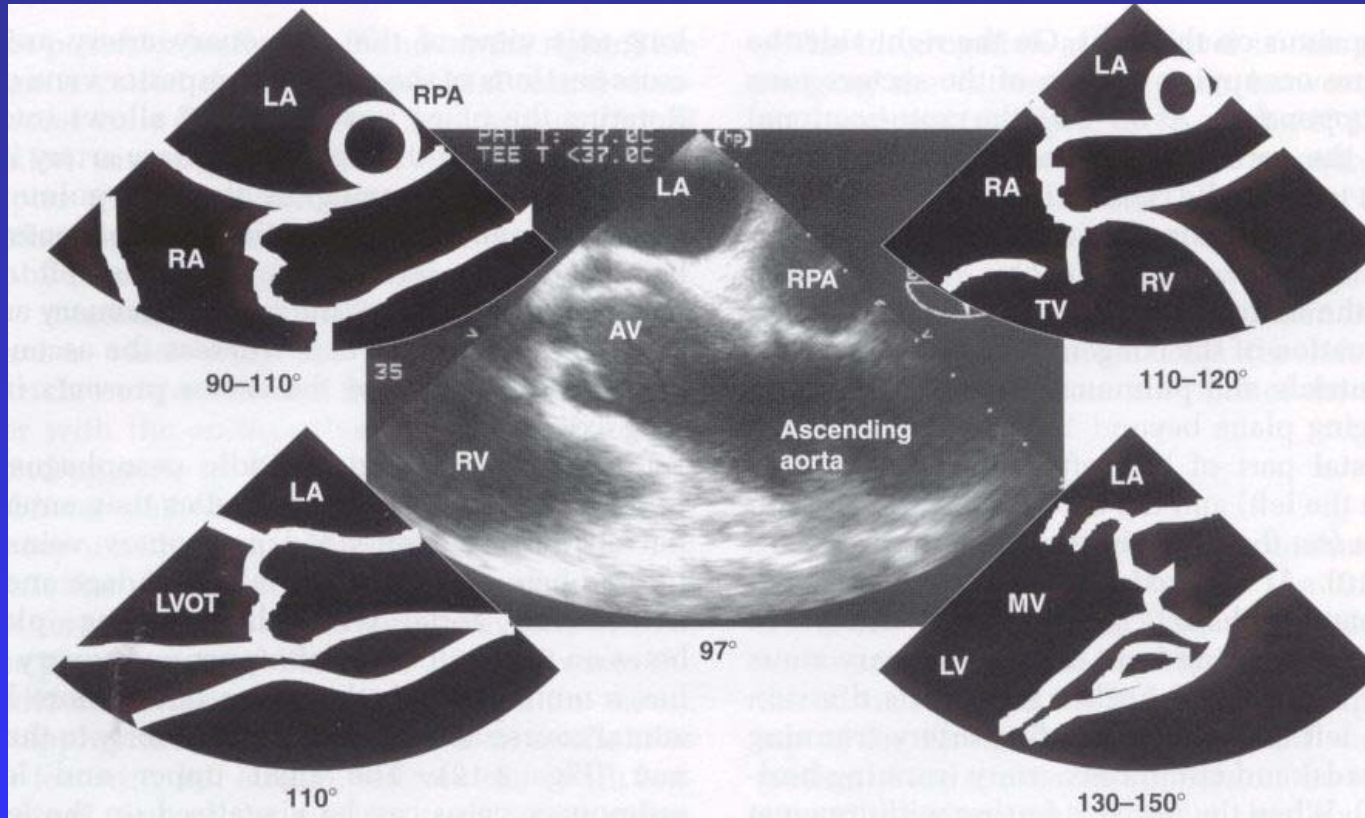
ME AV LAX



Two-Dimensional Echocardiography

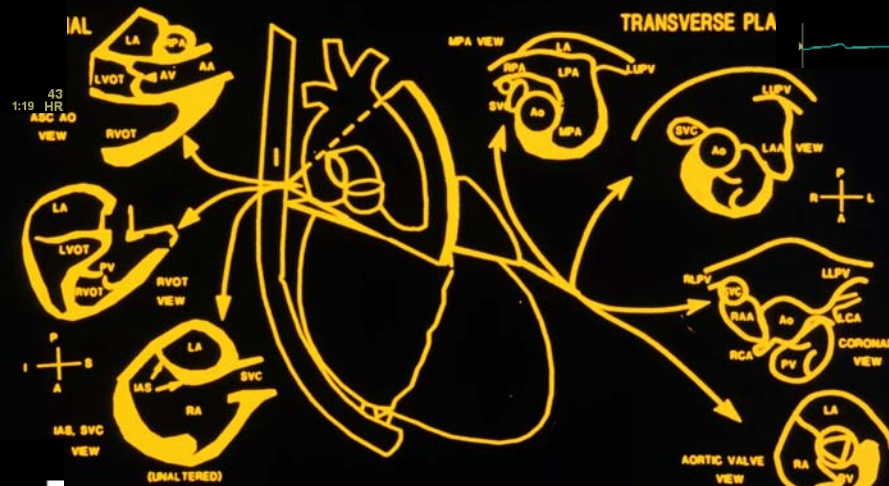
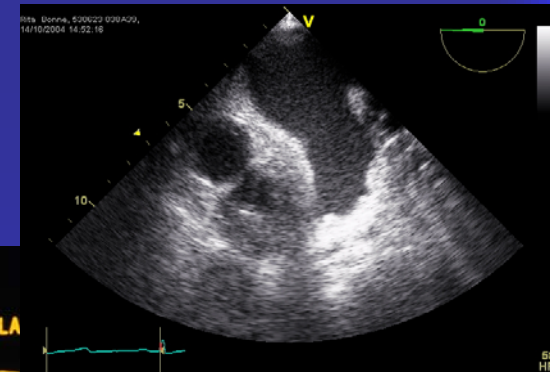
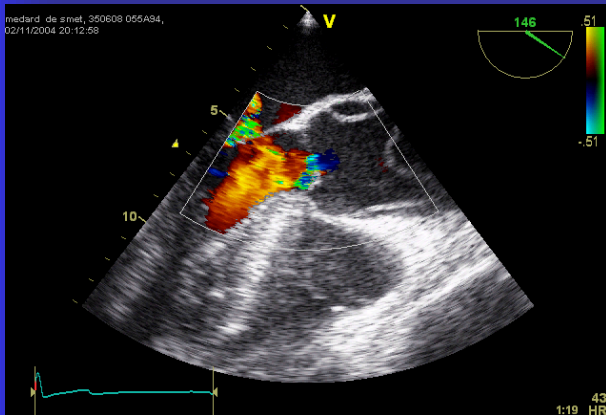
A Comprehensive Approach: Aortic Views

ME AV LAX

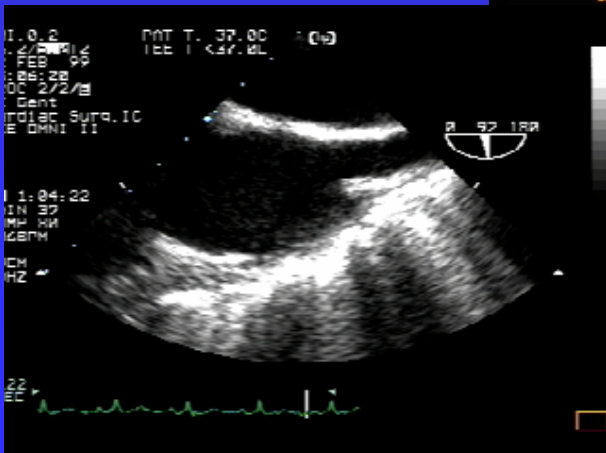


Two-Dimensional Echocardiography

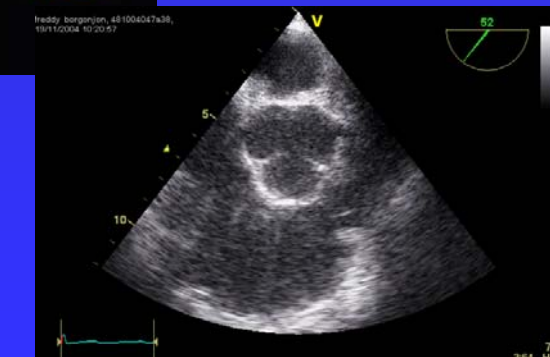A Comprehensive Approach



ME AV SAX

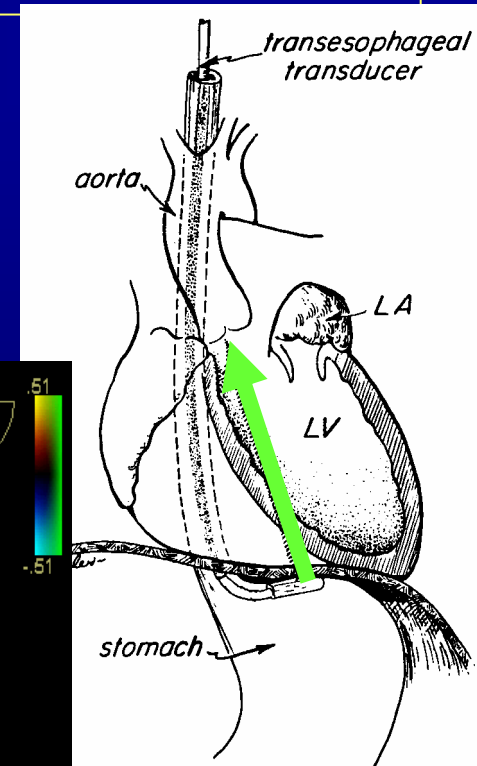
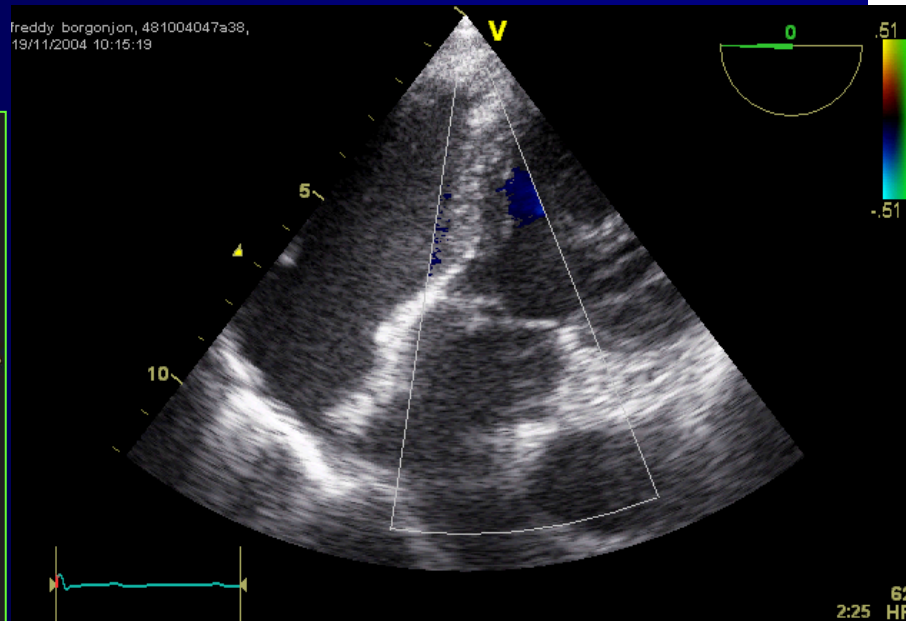
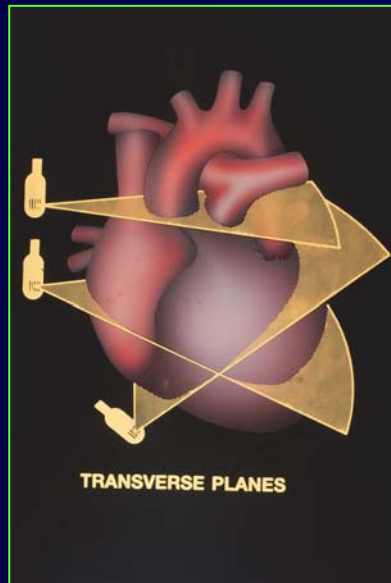


ME bicaval view



Two-Dimensional Echocardiography

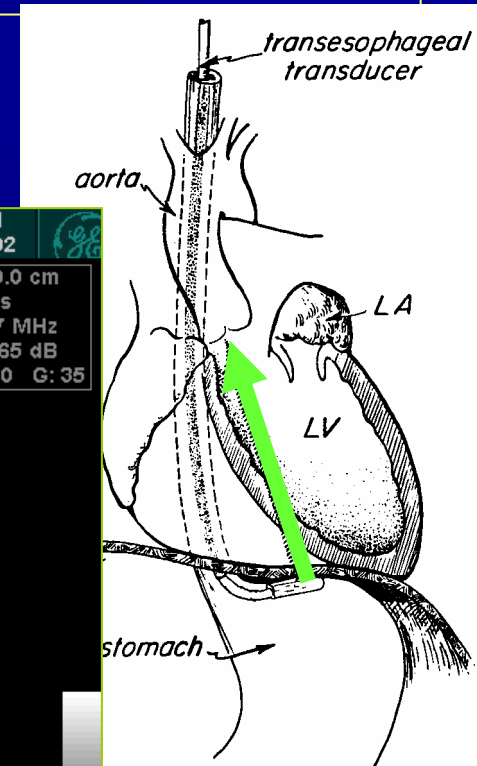
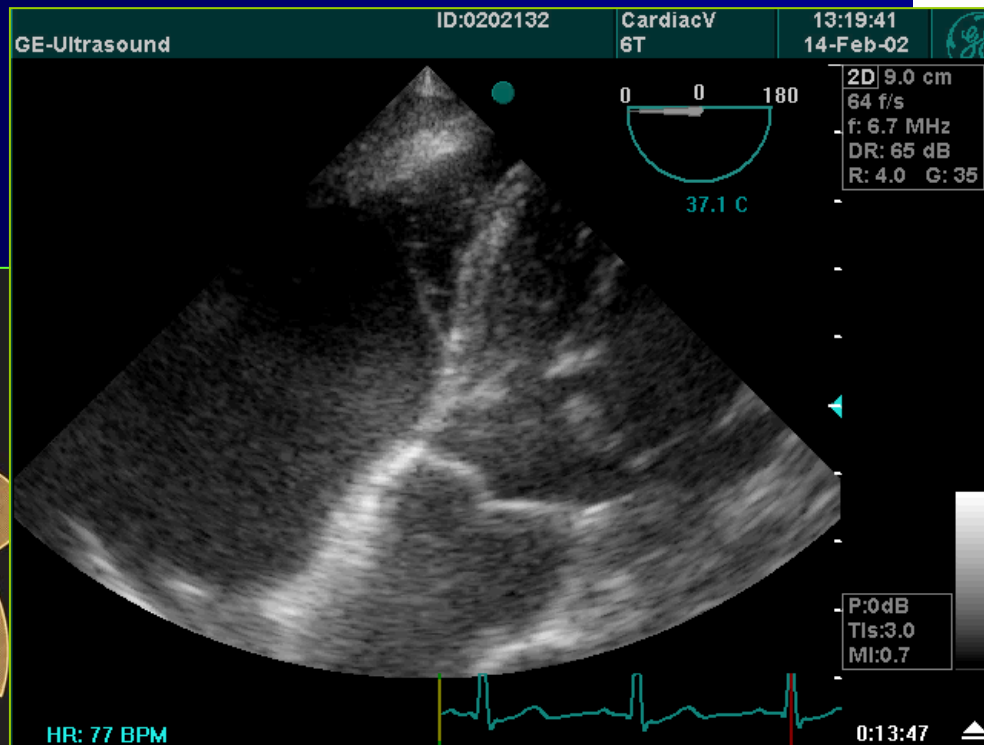
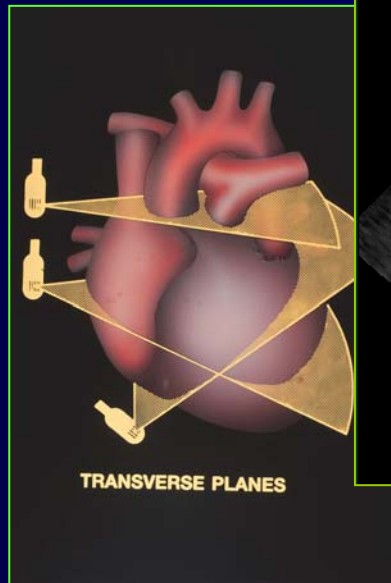
A Comprehensive Approach



Katz et al. Am J Card 1993;71:853-7

Two-Dimensional Echocardiography

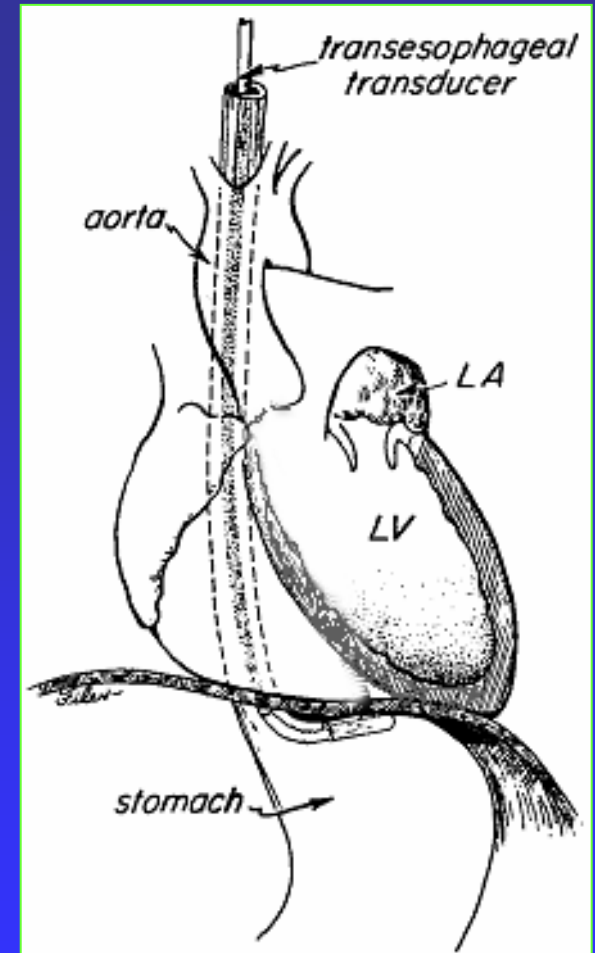
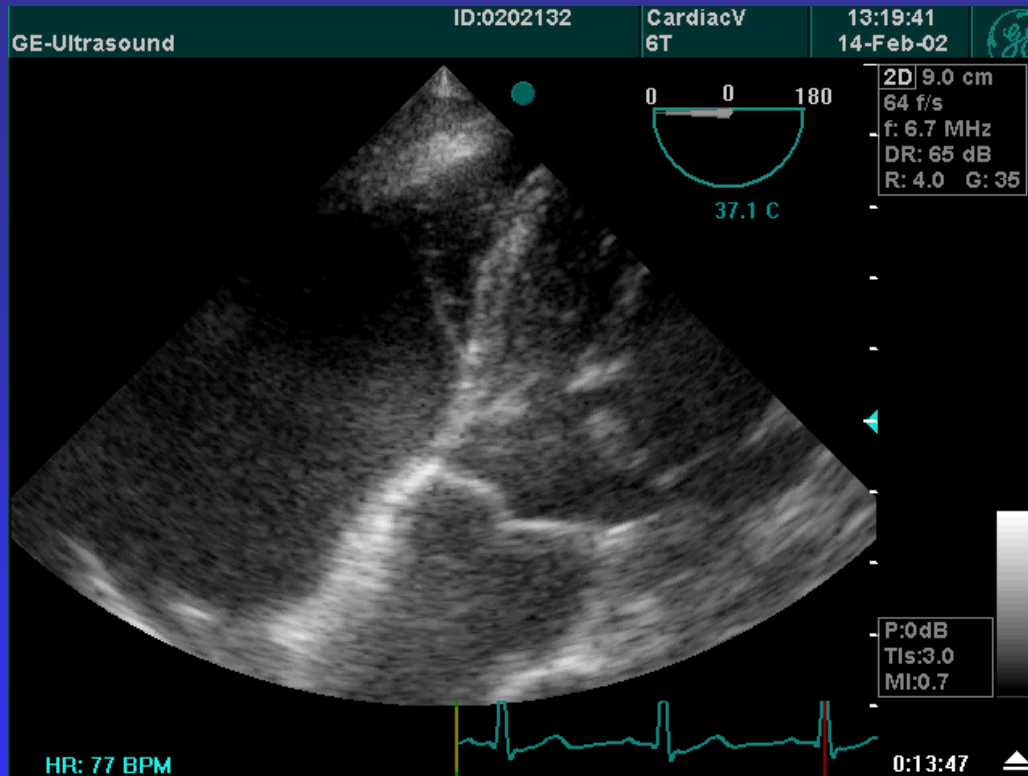
A Comprehensive Approach



Katz et al. Am J Card 1993;71:853-7

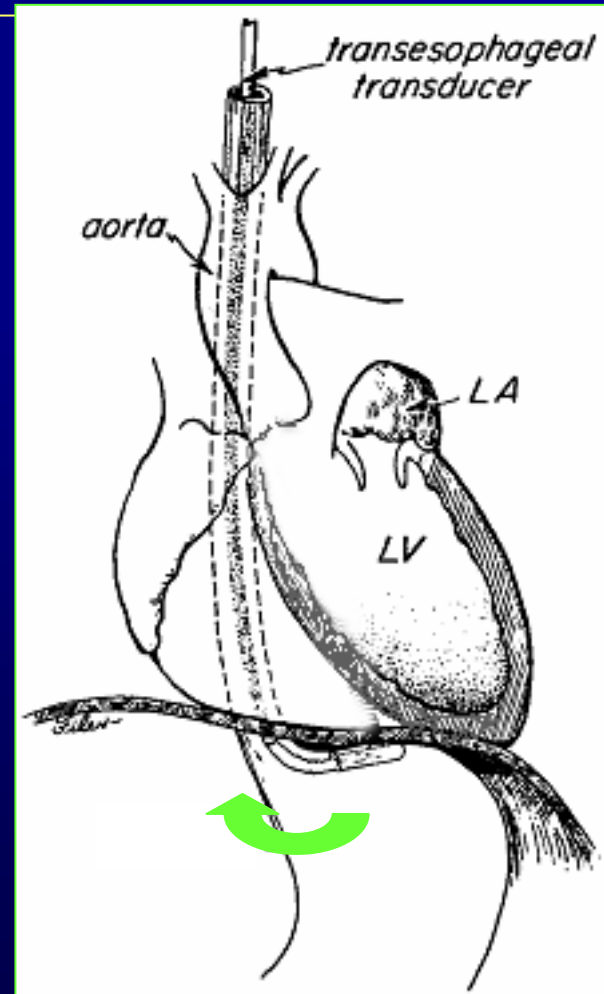
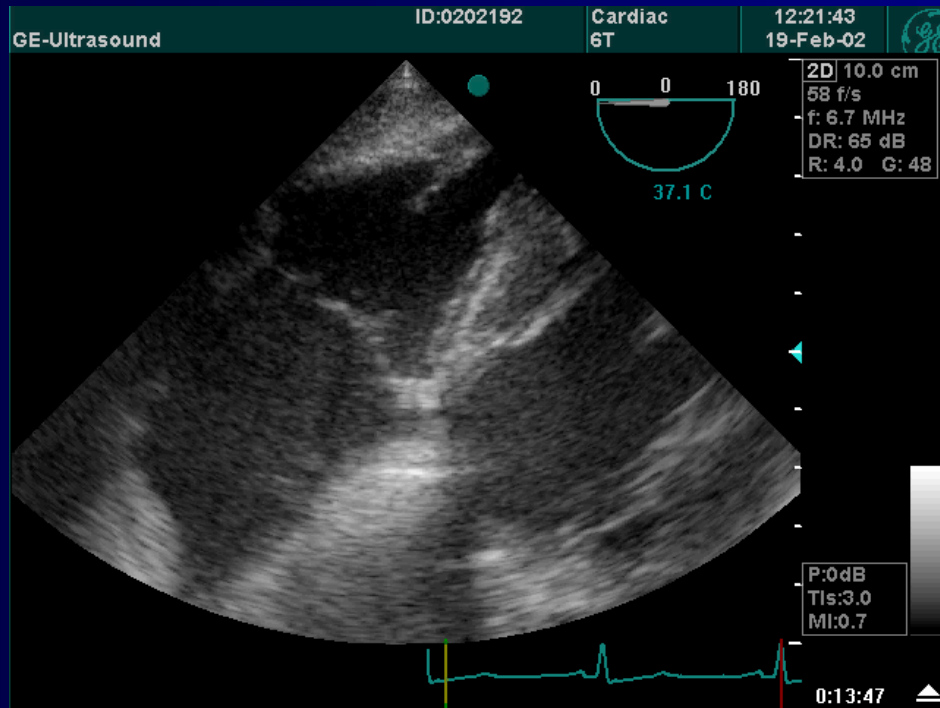
Two-Dimensional Echocardiography

A Comprehensive Approach



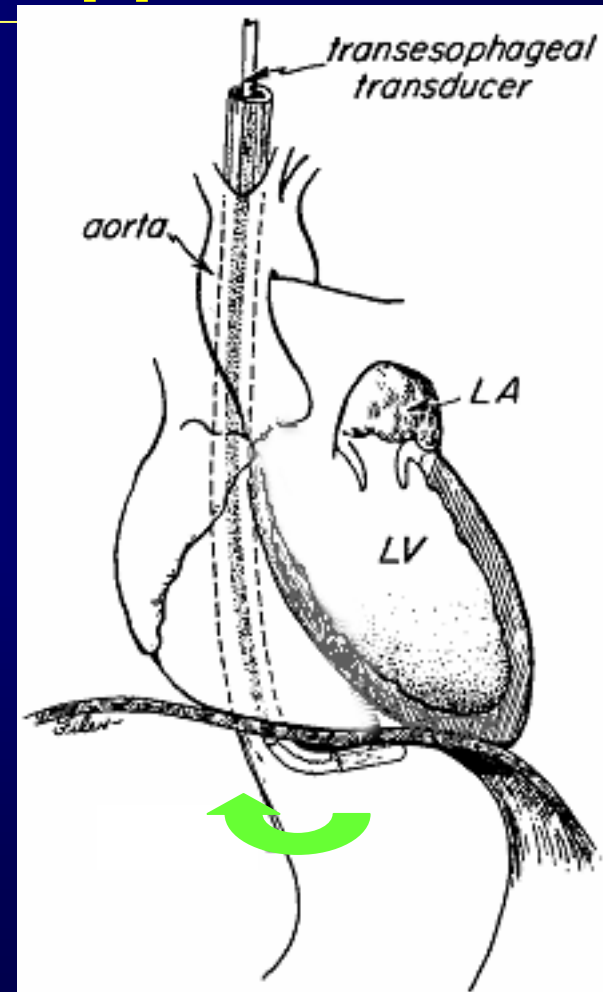
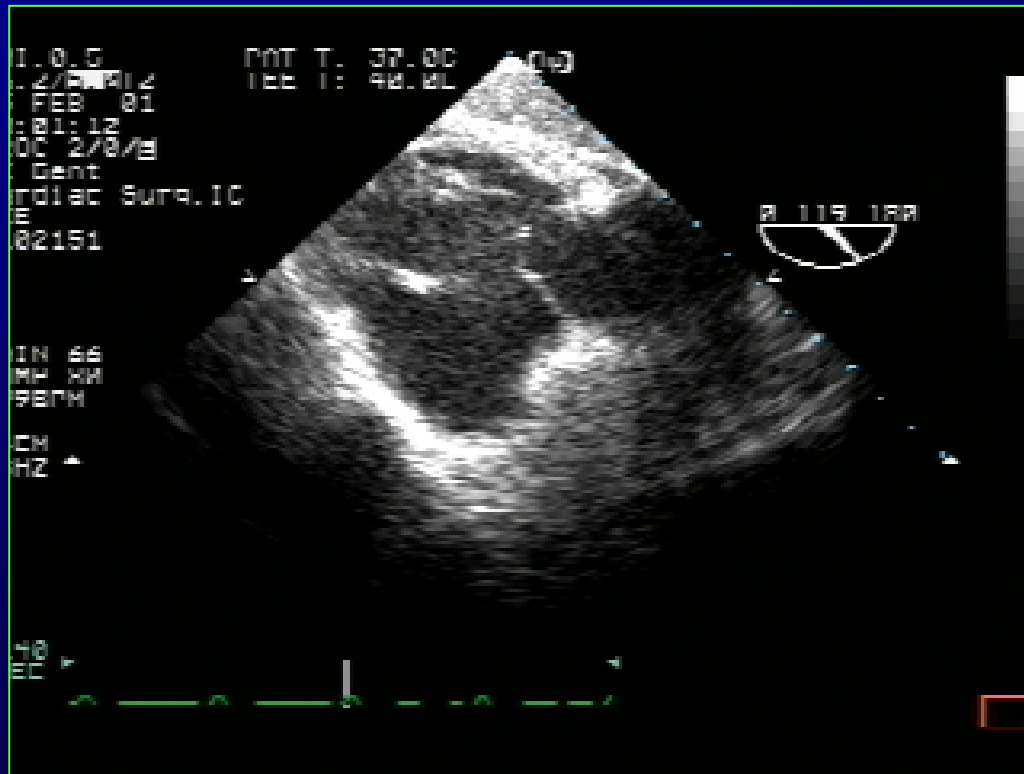
Two-Dimensional Echocardiography

A Comprehensive Approach



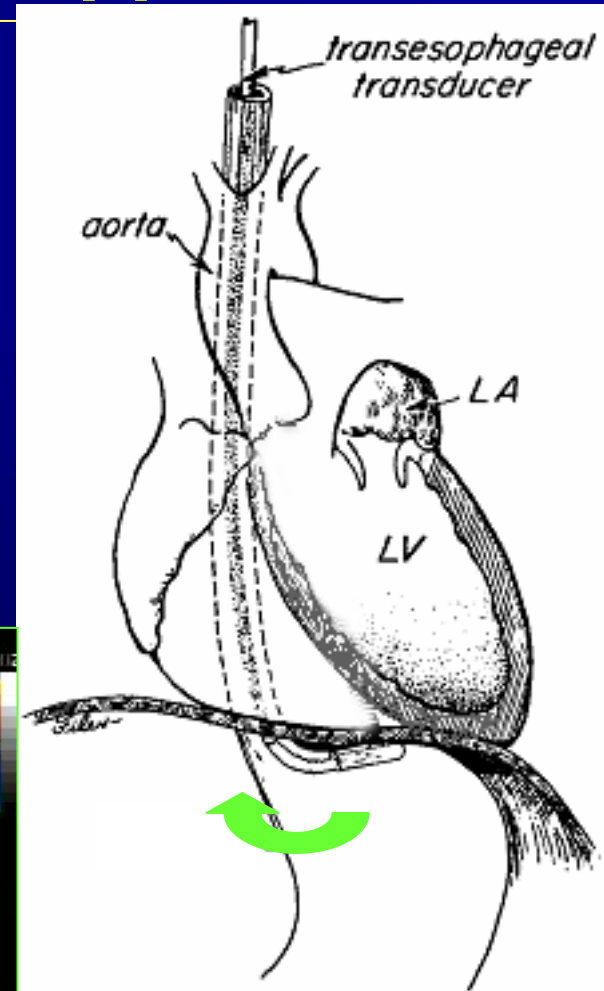
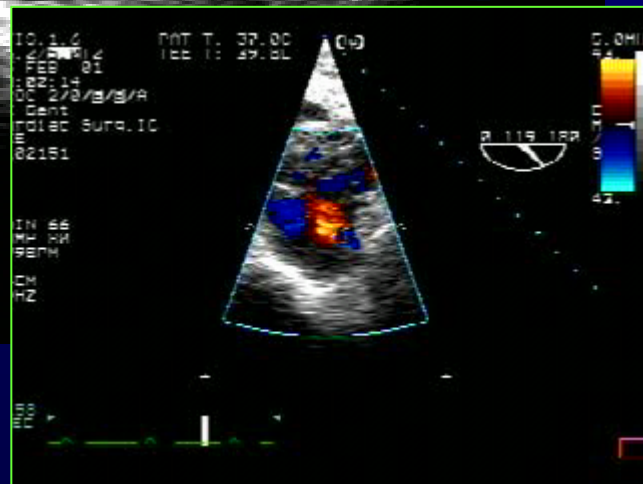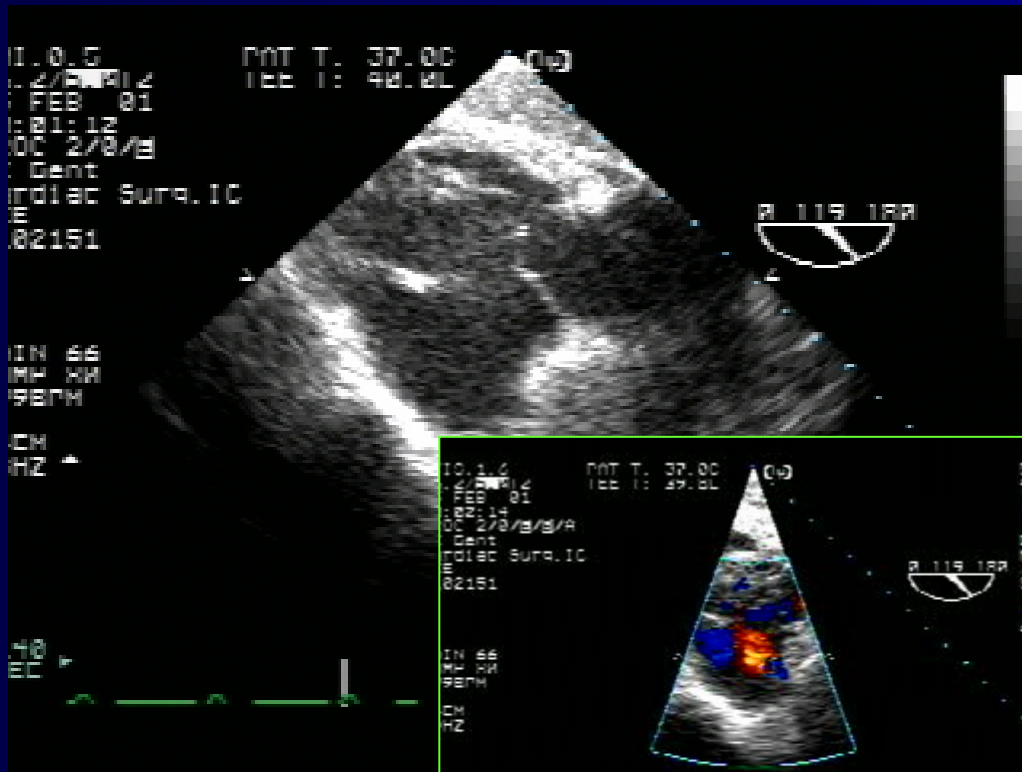
Two-Dimensional Echocardiography

A Comprehensive Approach



Two-Dimensional Echocardiography

A Comprehensive Approach



Maslow et al. A&A
1996;83:466-71

Two-Dimensional Echocardiography

A Comprehensive Approach

